

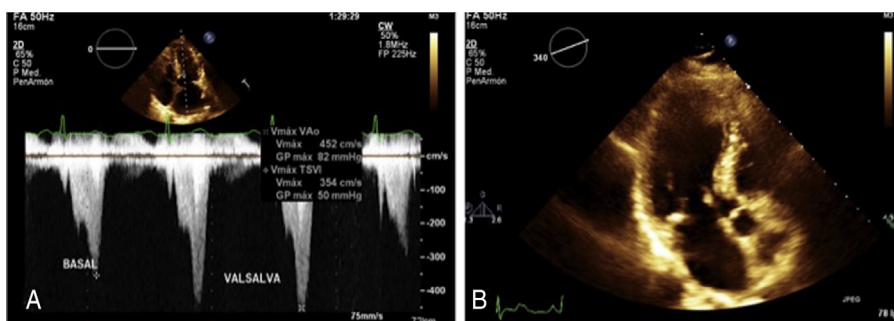
## SCIENTIFIC LETTERS

An unusual association of  
hypertrophic obstructive  
cardiomyopathyAsociación inusual de la miocardiopatía  
hipertrófica obstructiva

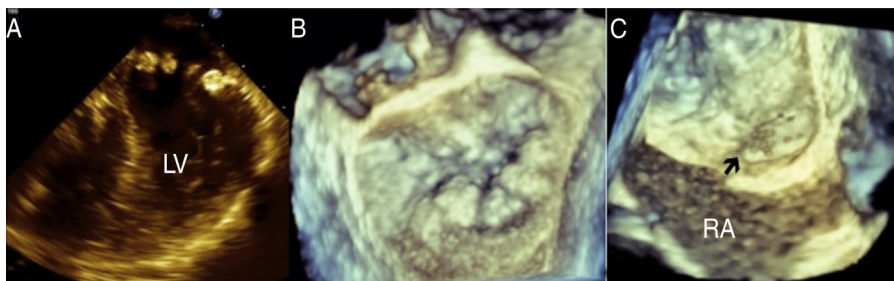
Sixty-six year-old woman with systemic hypertension treated with irbesartan. Her sister had history of patent foramen ovale (PFO). In 2008 she began with lipothymia associated with moderate physical effort, palpitations and exertional dyspnea. She denies migraine or headache. On physical examination a harsh diamond shaped systolic murmur was heard, which becomes quite loud with Valsalva maneuver. Transthoracic and transesophageal echocardiogram shows asymmetric septal hypertrophy (ASH) with left

ventricular outflow tract obstruction provoked by systolic anterior motion of the mitral valve at rest (50 mm Hg) or provocation (82 mm Hg), mitral annular calcification (MAC) with mild to moderate mitral regurgitation, left atrial enlargement (Fig. 1), mild tricuspid regurgitation, interatrial septal aneurysm with PFO, left ventricular ejection fraction of 77%, global longitudinal deformation of  $-20\%$  and TAPSE of 22 mm. Transesophageal echocardiogram corroborates the presence of ASH and MAC simulating a pearl necklace, interatrial septal aneurysm with PFO with abundant bubbles passing from right to left in the agitated saline contrast study (Fig. 2) and atheromatous plaques in the aortic arch were detected. She is receiving medical treatment with beta-blocker, and oral anticoagulation and is programmed for alcohol septal ablation.

Hypertrophic cardiomyopathy is a primary disease of the myocardium, characterized by the presence of an abnor-



**Figure 1** (A) Transthoracic echocardiography showing left atrial enlargement. Continuous wave Doppler with left ventricular outflow tract obstruction at baseline, which increases with Valsalva maneuver (B) Apical 3 chamber view showing septal hypertrophy and calcification of the mitral annulus.



**Figure 2** Transesophageal two and three-dimensional echocardiography showing mitral annular calcification (A and B) and patent foramen ovale in the study with agitated saline contrast, black arrow (C). Abbreviations: LV: left ventricle; RA: right atrium.

mal hypertrophy of the left ventricle, affecting one in 500 of the general population. Approximately two-third of the patients have left ventricular outflow tract obstruction. The onset and severity of symptoms varies widely, many people do not have symptoms but others experience severe complications, including arrhythmias, shortness of breath with exertion, chest pain, dizziness and fainting spells, dilated cardiomyopathy, mitral valve problems and sudden cardiac death. Sudden cardiac death is estimated to occur in about 1% of patients of all ages each year, but this condition is most often in younger people (<30 years-old). Recently, Haruki et al.,<sup>1</sup> found that in hypertrophic cardiomyopathy, the incidence of stroke and embolic events is about 1.0% per year; older age and enlargement of left atrium are considered possible risk factors for embolic events in patients with hypertrophic cardiomyopathy without documented atrial fibrillation. The echocardiography is the method of choice in the diagnosis and follow-up of these patients.<sup>2</sup>

The mitral annular calcification (MAC) is a chronic, degenerative process in the fibrous base of the mitral valve, associated with both a degenerative process such as atherosclerosis and abnormalities in the metabolism of calcium-phosphorus. MAC may be considered a potential cause of thromboembolism as a mass having propensity for thrombus formation.

The ASH associated with MAC increases with age with a prevalence of 0% at 60 years, 14% at 70, 16% at 80 and 29% at 90 years,<sup>3</sup> also it is associated with sudden death.<sup>4</sup>

It was described that the presence of PFO increases the risk of stroke of 25% in the general population to 30–40%.<sup>5</sup>

The association between these three pathologies is uncommon and increase the risk of stroke and sudden death. Our patient, despite having important risk factors for stroke, has not yet presented any symptoms suggestive of cerebral infarction, because she has a close medical monitoring.

## Conclusions

1. The association of obstructive hypertrophic cardiomyopathy with mitral annular calcification and patent foramen ovale is uncommon.
2. This association increases the risk of sudden death and stroke.
3. These patients need a closer monitoring in order to avoid a fatal outcome.
4. The echocardiography is the method of choice for diagnosis and follow-up of these patients.

## Funding

None declared.

## Conflict of interests

There is no conflict of interest between the authors.

## References

1. Haruki S, Minami Y, Hagiwara N. Stroke and embolic events in hypertrophic cardiomyopathy Risk Stratification in patients without atrial fibrillation. *Stroke*. 2016;47, <http://dx.doi.org/10.1161/STROKEAHA.115.012130>
2. Weissler-Snir A, Crean A, Rakowski H. The role of imaging in the diagnosis and management of hypertrophic cardiomyopathy. *Expert Rev Cardiovasc Ther*. 2016;14:51–74.
3. Abramowitz Y, Jilaihawi H, Chakravarty T, et al. Mitral annulus calcification. *J Am Coll Cardiol*. 2015;27:1934–41.
4. Norby FL, Wilsdon T, Alonso A, et al. Echocardiographic predictors of sudden cardiac death: the atherosclerosis risk in communities study and cardiovascular health study. *Circ Cardiovasc Imag*. 2016;9:e004431, <http://dx.doi.org/10.1161/CIRCIMAGING.115.004431>
5. Bang OY, Lee MJ, Ryoo S, et al. Patent foramen ovale and stroke-current status. *J Stroke*. 2015;17:229–37.

Georgina E. Segoviano-Mendoza<sup>a</sup>,  
Ramon Villavicencio-Fernández<sup>b</sup>,  
Nilda Espinola-Zavaleta<sup>c,d,\*</sup>

<sup>a</sup> *Cardiology Department, ABC Medical Center, I.A.P, Mexico City, Mexico*

<sup>b</sup> *Hemodynamics Department, ABC Medical Center, I.A.P, Mexico City, Mexico*

<sup>c</sup> *Echocardiography Department, ABC Medical Center, I.A.P, Mexico City, Mexico*

<sup>d</sup> *Nuclear Medicine Department, National Institute of Cardiology Ignacio Chavez, Mexico City, Mexico*

\* Corresponding author at: National Institute of Cardiology Ignacio Chavez, Juan Badiano 1, Colonia Sección XVI, Tlalpan, P.C: 14080 Mexico City, Mexico.

E-mail address: [niesza2001@hotmail.com](mailto:niesza2001@hotmail.com) (N. Espinola-Zavaleta).

<https://doi.org/10.1016/j.acmx.2017.08.004>  
1405-9940/

© 2017 Instituto Nacional de Cardiología Ignacio Chávez. Published by Masson Doyma México S.A. This is an open access article under the CC BY-NC-ND license (<http://creativecommons.org/licenses/by-nc-nd/4.0/>).