

## SCIENTIFIC LETTERS

### “Buddy wire” technique in transcatheter aortic valve implantation with a balloon-expandable valve: A rescue option in the setting of direct valve implantation (without predilation)



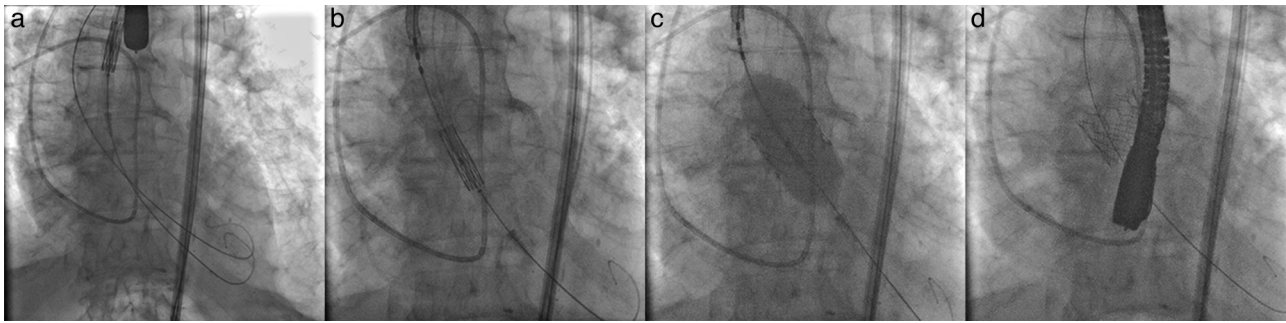
### Técnica “Buddy wire” en implantación de válvula aórtica transcatóter con válvula expandible con balón: una opción de rescate en casos con implantación directa de válvula (sin predilatación)

Transcatheter aortic valve implantation (TAVI) is a viable treatment option severe aortic stenosis in patients deemed to be at high surgical risk. Despite the favorable results of this procedural technique, concomitant medical comorbidities contribute to peri- and post-procedural morbidity and mortality in patients undergoing TAVI.<sup>1</sup> Additional procedural factors such as the need for valve predilation, prolonged or repeated rapid pacing also contribute to procedural risk, particularly in those with heart failure or pulmonary hypertension with resultant loss of ventricular interdependence.<sup>2</sup> Some authors have shown that microvascular tissue perfusion is affected during rapid pacing while performing a transcatheter aortic valve replacement. Rapid ventricular pacing may lower coronary blood flow from 25% with an 8-second rapid-pacing run up to 50% at a 18-second rapid-pacing run.<sup>3</sup> Although mean arterial pressure is recovered rapidly, microvascular perfusion arrest (“no flow”) occurs in a significant proportion of patients and becomes more likely with prolonged rapid pacing.<sup>4</sup> Also rapid pacing may promote ventricular arrhythmias and hypotension. When added to pulmonary hypertension, this effect could be catastrophic due to an imbalance on preload, afterload and contractility.<sup>5</sup> Interestingly, prior reports have shown the feasibility of direct transcatheter valve implantation without valve predilation.<sup>6</sup> To this effect, we describe the case of a patient deemed at extremely high surgical risk for conventional surgical aortic valve

replacement, complicated by severe pulmonary hypertension, who underwent TAVI. It was decided by the Heart Team to not perform valve predilation before the procedure was begun in order to minimize the risks related to rapid ventricular pacing. During the procedure, it was necessary to improvise as the absence of valve predilation made it impossible to cross the annulus with the transcatheter aortic valve. We adopted the “buddy wire” technique as an effective tool to cross the aortic valve on this case with severe calcified aortic stenosis without valve predilation.

A 90-year-old frail man was referred to the Quebec Heart and Lung Institute for the management of rapidly progressing dyspnea (New York Heart Association class 4). Investigations revealed severe aortic stenosis with a mean transvalvular gradient of 70 mmHg, aortic valve area: 0.4 cm<sup>2</sup>, peak pulmonary artery systolic pressure of 75 mmHg, left ventricular ejection fraction of 35%, and angiographically normal coronary arteries. Following Heart Team evaluation, his advanced age, markedly raised pulmonary artery pressures, frailty, and high STS-PROM and logistic EuroSCORE scores (8.1% and 20.6% respectively), TAVI was offered as an alternative treatment option. Furthermore, it was also felt that native valve predilation with rapid pacing would likely be poorly tolerated, largely due to his severe pulmonary hypertension and concomitant severe biventricular systolic dysfunction.

The procedure was performed via the right transfemoral approach, under general anesthesia, using fluoroscopic and echocardiographic guidance. The left femoral artery was used to advance a 5-Fr pigtail catheter as a reference catheter. Crossing of the aortic valve catheter was performed with an Argon 0.035” straight guide wire (Argon Medical Devices Inc, Athens, TX, USA) followed by a 260 cm Amplatz extra stiff guide wire (Cook Medical, Bloomington, IN, USA) positioned in the left ventricle. Subsequently, attempts were made to introduce a 26 mm SAPIEN 3 balloon expandable valve (Edwards Lifesciences Inc, Irvine, CA, USA) within the aortic annulus. However this was unsuccessful due to the severity of aortic stenosis and valve calcification. Given the hesitancy to perform valve predilation due to the patient’s fragile hemodynamic condition, via left transfemoral arterial access, a second Argon 0.035” straight guide wire was advanced into the left ventricle



**Figure 1** (a) Two guidewires were positioned in left ventricle with “buddy wire” technique. (b) Prosthesis was carefully positioned on aortic annulus. (c) Transcatheter valve being deployed on aortic annulus. (d) Transcatheter heart valve successfully deployed and being verified.

and then exchanged for a 260 cm Amplatz extra stiff guide wire (Fig. 1a). Using a “buddy wire” technique, the transcatheter heart valve was successfully positioned within the aortic annulus. The second guide wire was immediately withdrawn and the valve was adequately positioned within the aortic annulus (Fig. 1b). Prosthesis positioning was echocardiographically verified and a very short burst of rapid pacing with simultaneous balloon inflation was performed for valve deployment (Fig. 1c). Angiographic and echocardiographic control images showed satisfactory valve position (Fig. 1d). There was no residual aortic valve regurgitation. We observed left ventricular recovery without stunning and pulmonary arterial pressures were unchanged. Post-intervention, the patient’s condition remained stable, without complication, and he was discharged from hospital 72 h post-TAVI.

It has been shown that rapid pacing on TAVI has some consequences on coronary blood flow specially on those with 8-second runs or longer, causing left ventricle stunning and a period of hypotension right after the stimuli.<sup>7</sup> Nonetheless, pulmonary arterial hypertension is a major risk factor for mortality during transcatheter valve implantation and cardiac surgery.<sup>1,8,9</sup> The resultant increase in right ventricular afterload coupled with the inability of the right ventricle to adapt to this hemodynamic stress is closely tied with poor survival. Right heart failure, the end result of pulmonary arterial hypertension, is responsible for 70% of deaths in this patient group. Therefore, in patients whose ventricular interdependence is severely compromised, specific measures and extreme caution during TAVI are required for minimizing the risk of severe periprocedural hemodynamic compromise. In such situations, avoiding or minimizing rapid pacing needs to be strongly considered. This however provides hindrance for optimal valve positioning. Nevertheless, this challenge may be overcome using the “buddy wire” technique for crossing the aortic annulus, thus avoiding aortic balloon valvuloplasty, but not the ability to successfully perform transcatheter aortic valve implantation.<sup>10</sup>

In conclusion, extreme heart failure or severe pulmonary hypertension can result in loss of ventricular interdependence, and subsequent increased morbidity and mortality may occur when repeated or prolonged rapid pacing during TAVI is undertaken leading to disastrous results. In

the latter cases, it may be advisable to avoid predilatation of the aortic valve. Yet, to overcome the difficulty of crossing the severely stenosed aortic valve, the “buddy wire” technique may be strongly considered to avoid valve predilatation in cases where valve crossing with the endoprosthesis is difficult and valve predilatation is not possible.

## References

1. Rodés-Cabau J. Transcatheter aortic valve implantation: current and future approaches. *Nat Rev Cardiol.* 2011;9:15–29.
2. Hsia HH, Haddad F. Pulmonary hypertension: a stage for ventricular interdependence. *J Am Coll Cardiol.* 2012;59:2203–5.
3. Selle A, Figulla HR, Ferrari M, et al. Impact of rapid ventricular pacing during TAVI on microvascular tissue perfusion. *Clin Res Cardiol.* 2014;103:902–11.
4. Lauten A, Selle A, Ferrari M, et al. Rapid ventricular pacing during TAVI frequently induces arrest and delayed recovery of microvascular perfusion. *Eur Heart J.* 2013;34:985.
5. Billings FR, Kidali SK, Shanewise JS. Transcatheter aortic valve implantation: anesthetic considerations. *Anesth Analg.* 2009;108:1453–62.
6. García E, Martín P, Hernández R, et al. Feasibility and safety of transfemoral implantation of Edwards SAPIEN XT prosthesis without balloon valvuloplasty in severe stenosis of native aortic valve. *Catheter Cardiovasc Interv.* 2014;83:791–5.
7. Witzke C, Don CV, Cubeddu RJ, et al. Impact of rapid ventricular pacing during percutaneous balloon aortic valvuloplasty in patients with critical aortic stenosis: should we be using it. *Catheter Cardiovasc Interv.* 2012;15:444–5.
8. Thunberg CA, Gaitan BD, Grewal A, et al. Pulmonary hypertension in patients undergoing cardiac surgery: pathophysiology, perioperative management, and outcomes. *J Cardiothorac Vasc Anesth.* 2013;27:551–72.
9. Rodés-Cabau J, Webb JG, Cheung A, et al. Transcatheter aortic valve implantation for the treatment of severe symptomatic aortic stenosis in patients at very high or prohibitive surgical risk: acute and late outcomes of the multicenter Canadian experience. *J Am Coll Cardiol.* 2009;55:1080–90.

10. Sheiban I, Infantino V, Bollati M. Buddy balloon to deliver a percutaneous aortic valve device: a percutaneous shoehorn. *Catheter Cardiovasc Interv.* 2009;74:805–7.

Ricardo Allende, Rishi Puri, Éric Dumont, María del Trigo, Omar Abdul-Jawad Altisent, Josep Rodés-Cabau\*

Department of Cardiology, Quebec Heart and Lung Institute, Laval University, Quebec City, Quebec, Canada

\*Corresponding author at: Quebec Heart & Lung Institute, Laval University, 2725 Chemin Sainte-Foy, G1V 4G5 Quebec, QC, Canada.

E-mail address: [josep.rodés@criucpq.ulaval.ca](mailto:josep.rodés@criucpq.ulaval.ca) (J. Rodés-Cabau).

<http://dx.doi.org/10.1016/j.acmx.2016.01.004>

## Tetralogía de Fallot con atresia pulmonar y circulación pulmonar poco habitual



## Tetralogy of Fallot with pulmonary atresia and a very unusual pulmonary circulation

### Presentación del caso

La tetralogía de Fallot con atresia pulmonar es una malformación cardíaca caracterizada por la ausencia de conexión entre el ventrículo derecho y el tronco de la arteria pulmonar, la cual puede ser secundaria a una obstrucción infundibular o valvular; existe también una comunicación interventricular posterior y la aorta puede ser biventricular o nacer totalmente del ventrículo derecho<sup>1</sup>. Lo que hace más interesante esta cardiopatía es lo diversa que puede ser la circulación pulmonar. Se han descrito distintas formas de irrigación de los segmentos pulmonares en esta malformación, pero nunca con el nacimiento de una rama pulmonar desde la arteria coronaria, motivo por el cual presentamos este caso.

Paciente femenina de 6 meses de edad con historia de cianosis generalizada desde el nacimiento; quien ingresó por aumento de la cianosis. Los hallazgos relevantes a la exploración física fueron saturación 76%, soplo continuo infraclavicular izquierdo, pulsos amplios en las 4 extremidades y ligera deformación de lechos ungueales. El electrocardiograma ritmo sinusal, dextrorrotación, crecimiento de cavidades derechas (fig. 1a). La radiografía de tórax con *situs solitus* bronquial, índice cardiorádico de 0,61, punta levantada, cono de la pulmonar abombado, rama pulmonar derecha prominente, sin observar la izquierda, arco aórtico izquierdo y oligohemia en ápices pulmonares (fig. 1b). El ecocardiograma mostró tetralogía de Fallot con atresia pulmonar sin visualizar las ramas pulmonares, por lo que se realizó cateterismo cardíaco encontrando presiones ventriculares igualadas (80/10/12 mmHg), circulación pulmonar dada por ramas pulmonares no confluentes; la derecha naciendo del tronco de la coronaria izquierda (fig. 1c) y la izquierda del conducto arterioso, con estenosis en su origen (fig. 1d). Tenía 2 colaterales aortopulmonares derechas hipertensas; una irrigaba la porción apical del pulmón derecho (50/25/33 mmHg) y la otra, la porción media y basal ipsilateral (45/25/31 mmHg). Para caracterizar mejor el origen de la rama pulmonar derecha del tronco de la coronaria izquierda se realizó tomografía que corroboró el diagnóstico (fig. 1e).

Se manejó en 2 tiempos. Primero, embolización de colaterales aortopulmonares con dispositivos *coils*, y 6 días después se realizó cirugía de Rastelli, sección y sutura del origen de ambas ramas pulmonares confluyéndolas a la porción distal del injerto de yugular bovino (Contegra<sup>®</sup> de 14 mm), plastia en origen de rama pulmonar izquierda y cierre de la comunicación interventricular. Después de una mala evolución en el posquirúrgico se decide llevar nuevamente a cateterismo, encontrando estenosis en origen de rama pulmonar izquierda con gradiente de 35 mmHg y relación de presiones entre ventrículo derecho e izquierdo (pVD/pVI) de 0,62. Se realizó angioplastia con *stent* de rama izquierda (fig. 2a), con registro de presiones final (VD 35/6/12 mmHg vs VI 80/4/11 mmHg). Evolucionó hacia la mejoría con egreso 4 días después. La tomografía control sin zonas de estenosis en tronco ni ramas pulmonares (fig. 2b y 2c).

Actualmente, la paciente se encuentra en clase funcional I, bajo seguimiento a través de consulta externa.

La tetralogía de Fallot con atresia pulmonar es una entidad que requiere conocimiento del desarrollo embrionario. Las porciones proximales de las ramas de la arteria pulmonar habitualmente se originan a partir de los sextos arcos aórticos y las colaterales aortopulmonares desde la aorta descendente<sup>1</sup>. El nacimiento aórtico de la rama derecha se origina por una malposición del tabique aortopulmonar de Tandler que separa el cuarto arco aórtico izquierdo (origen del cayado aórtico) de los sextos arcos aórticos. Normalmente este tabique tiene una orientación inclinada de derecha a izquierda en sentido dorsoventral<sup>2</sup>. Proponemos como posible origen embriológico del nacimiento aórtico de una rama pulmonar, a la malposición del tabique aortopulmonar, el cual sería ectópico en sentido dorsoventral que determinaría que la rama pulmonar derecha naciera de la aorta ascendente y la rama izquierda del tronco pulmonar. La rama derecha puede cambiar de posición de manera descendente hasta llegar a la arteria coronaria izquierda tal como se ha descrito en este caso (fig. 2d).

En esta malformación la clínica depende de la circulación pulmonar. Si esta es unifocal (por un conducto arterioso) la cianosis marcada e hipoxemia aparecerán a edades tempranas pudiendo ocurrir la muerte si hay cierre del mismo<sup>3</sup>. Cuando es multifocal (colaterales aortopulmonares) las manifestaciones clínicas serán tardías pudiendo llegar a la vida adulta. Debido a esta diversidad de circulación pulmonar el cateterismo es obligatorio, ya que además de mostrar la anatomía informará presiones de las colaterales<sup>4</sup>.